

Nasal Septum

- an osteocartilaginous framework
- mainly bony

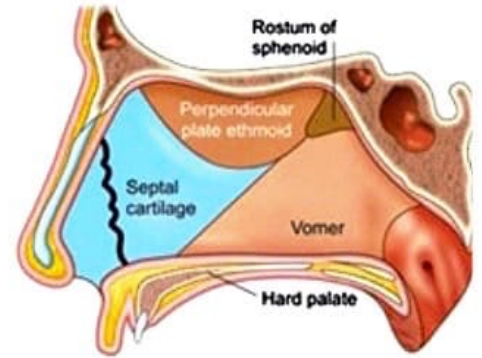
CONSISTS OF THREE PARTS

1. Columellar Septum
2. Membranous Septum
3. Septum proper/septal cartilage
(quadrate)

Fracture of nasal septum

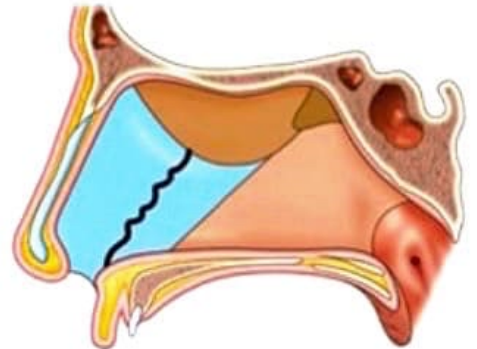
1. CHEVALLET FRACTURE

- Fracture of nasal bone + septum (**not deviated**)
- septum has vertical fracture
- results from blow from below(lateral blow)



2. JARJAWAY FRACTURE

- Fracture of nasal bone + septum (**septum deviated**)
- septum has horizontal / C shaped fracture
- lateral /frontal blow



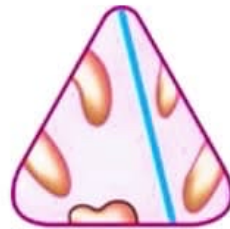@whymed

Deviated nasal septum

- MCC ; Birth Trauma (58%)

AETIOLOGY

- Trauma
- Developmental error
- Racial Factor
- Hereditary Factor



Caudal (Anterior) septal deviation



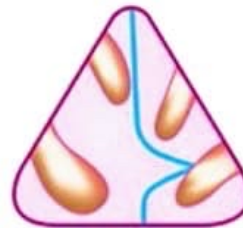C-shaped deviation



S-shaped deviation

TYPES

- Anterior dislocation
- C-shaped Deformity
- S-shaped Deformity
- Spurs
- Thickening



Septal spur



Septal thickening

CLINICAL FEATURES

Nasal Obstruction

Headache (sludger's neuralgia)

Nasal Discharge

Sinusitis

Acute Otitis Media

Epistaxis

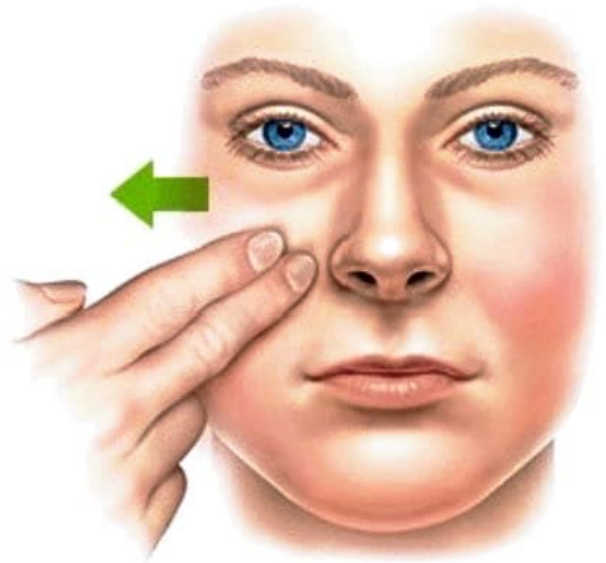Quadrate

Hyposmia

Anosmia

External Deformity

Middle Ear Infection



Cottle Maneuver

DIAGNOSIS

Cottle test

Cold Spatula Test

CT scan

@whymed

TREATMENT

○ minor degree of septal deviation with no symptoms require no treatment

○ surgery

- SMR(submucous resection operation)
- Septoplasty (preferred)

○ surgery can be done after 17 years

@whymed

Septal haematoma

AETIOLOGY

- Collection of blood under the perichondrium of nasal septum
- Cause; trauma or surgery

CLINICAL FEATURES

- Bilateral nasal obstruction
- Smooth rounded swelling
- Boggy & soft

Treatment

- Incision and drainage
- Small **anteroposterior** incision parallel to the nasal floor

Complications

- Saddle nose deformity
- Septal abscess and septal necrosis

@whymed

Perforation of nasal septum

AETIOLOGY

- Trauma (MC)
- Pathological
- Idiopathic
- Drugs and chemicals(cocaine abuse)

CLINICAL FEATURES

- Whistling sound
- obstruction
- crust

TREATMENT

- Keep the nose crust free by alkaline nasal douches
- Sialistic button - Small perforation
- Flap repaire- Large perforation

Thank you

@whymed